＜PDFNo.20220818-5＞　株式会社　山忠
URL: https://yamachutech.com/en/
Online Promotional VTR https://youtu.be/T3YiHY6bwnY

Part5.　MR 観察画像特集－①甲状腺

Mobile Rose 観察時に参考画像としてご使用ください。

★観察前のご注意：観察前に VC 表面の埃をテッシュで拭いて下さい

VC の埃



クリーンな表面

1）不適正/適正材料比較



2)不適正：血液のみ（細胞なし）

3)不適正：細胞なし



4）不適正：細胞なし、気泡のみ▼（中央に欠けのある球体）

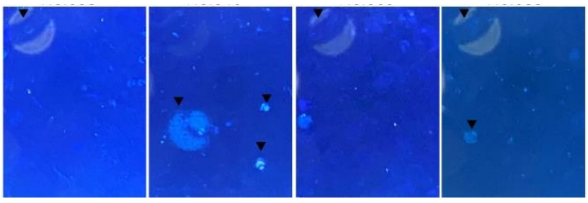

5）不適正：細胞なし、プラスチック片▼（光輝性のひも状物質）

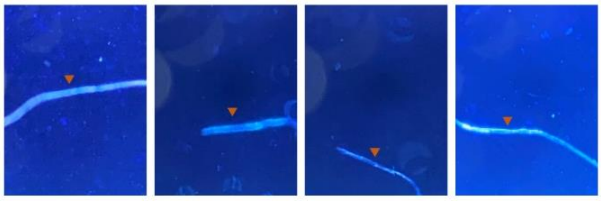

6）嚢胞内容液（緑変傾向）



7）コロイド▼（薄く平面的で大小不同、不規則な形状）

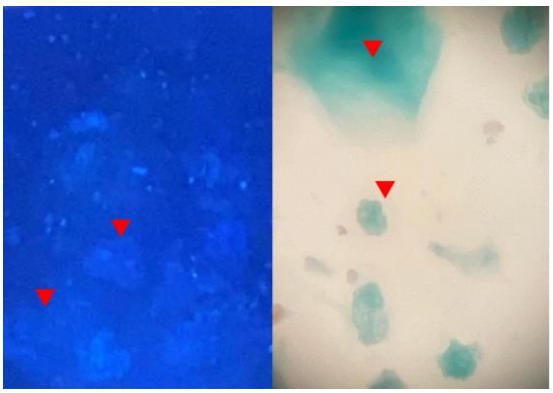

7）フィブリン塊　▼（不規則な集塊から突き出るファイバー状の突起が特徴）

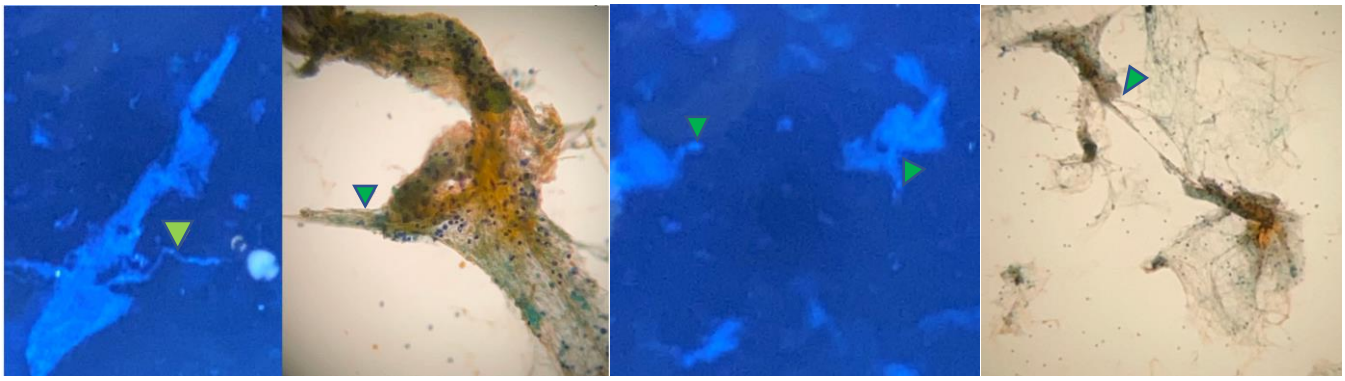

MR 観察像　PAP 染色　MR 観察像　PAP 染色

【良性：腺腫様甲状腺腫・腺腫様結節症例】　ROSE 適正

1）●気泡　▼濾胞上皮細胞（白く類円形～不規則な集塊）▼コロイドの混在例

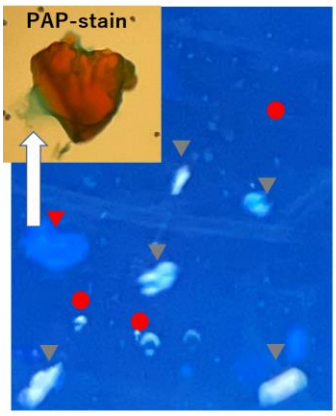



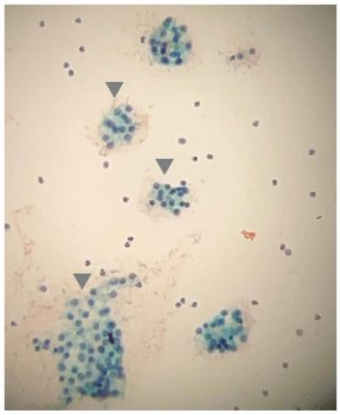

PAP 染色

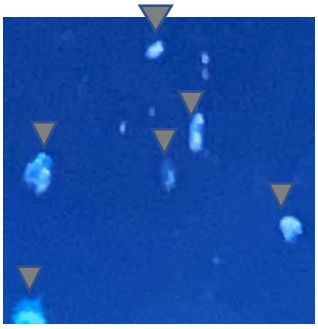

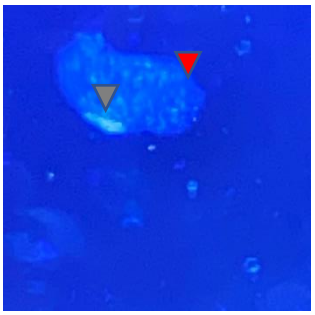

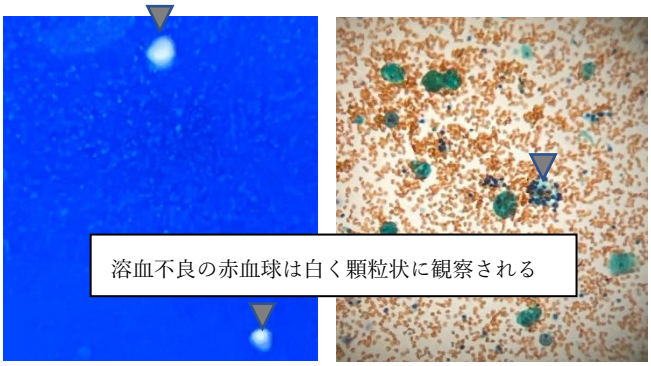

溶血不良の赤血球が背景に顆粒状に散見される中の厚く白い円形集塊（濾胞上皮細胞集塊）

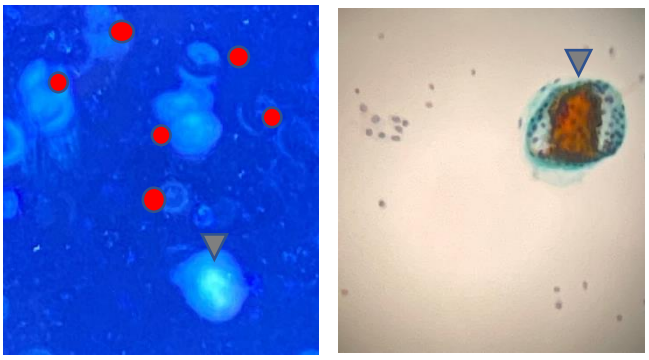

多数の気泡の混在と濾胞上皮細胞の中型集塊
PAP 染色では集塊内にコロイドがみられる

2）大型集塊例（淡青色、立体的な中～大型集塊▼）

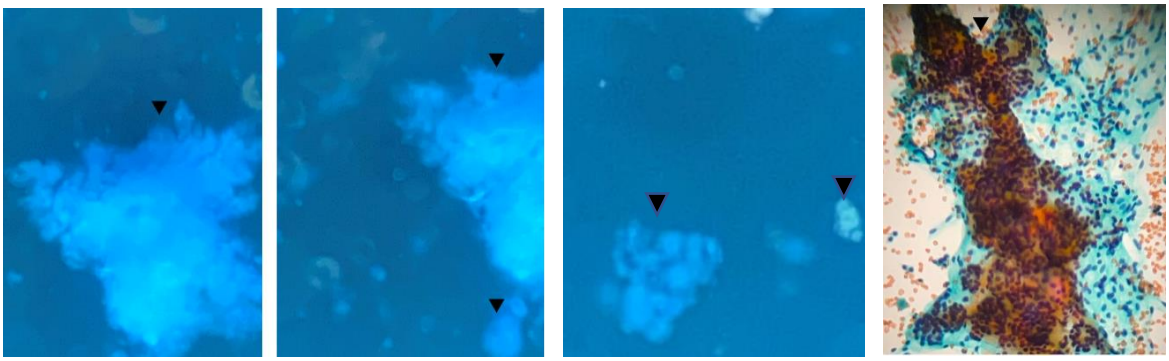

【良性：慢性甲状腺炎症例】　ROSE　適正

全体に焦点の合わない靄のような像が特徴（リンパ球の集簇）

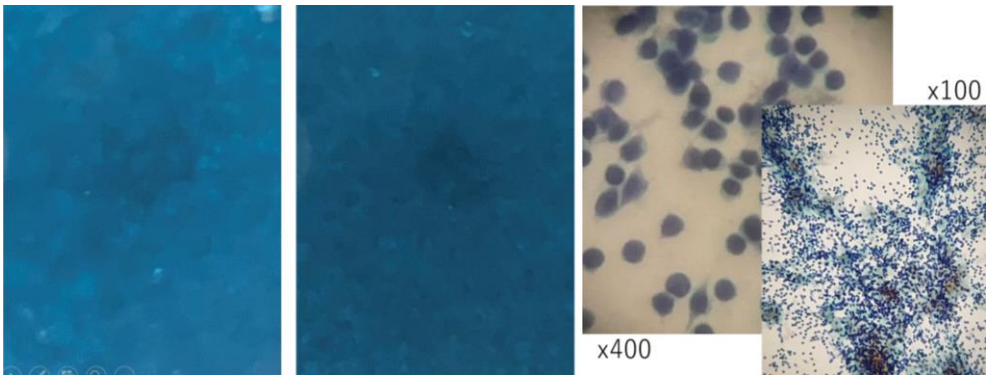

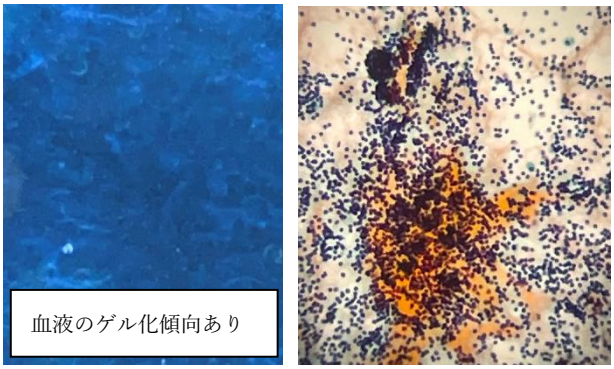

【悪性の疑い：濾胞性腫瘍の疑い】　▼濾胞上皮細胞集塊

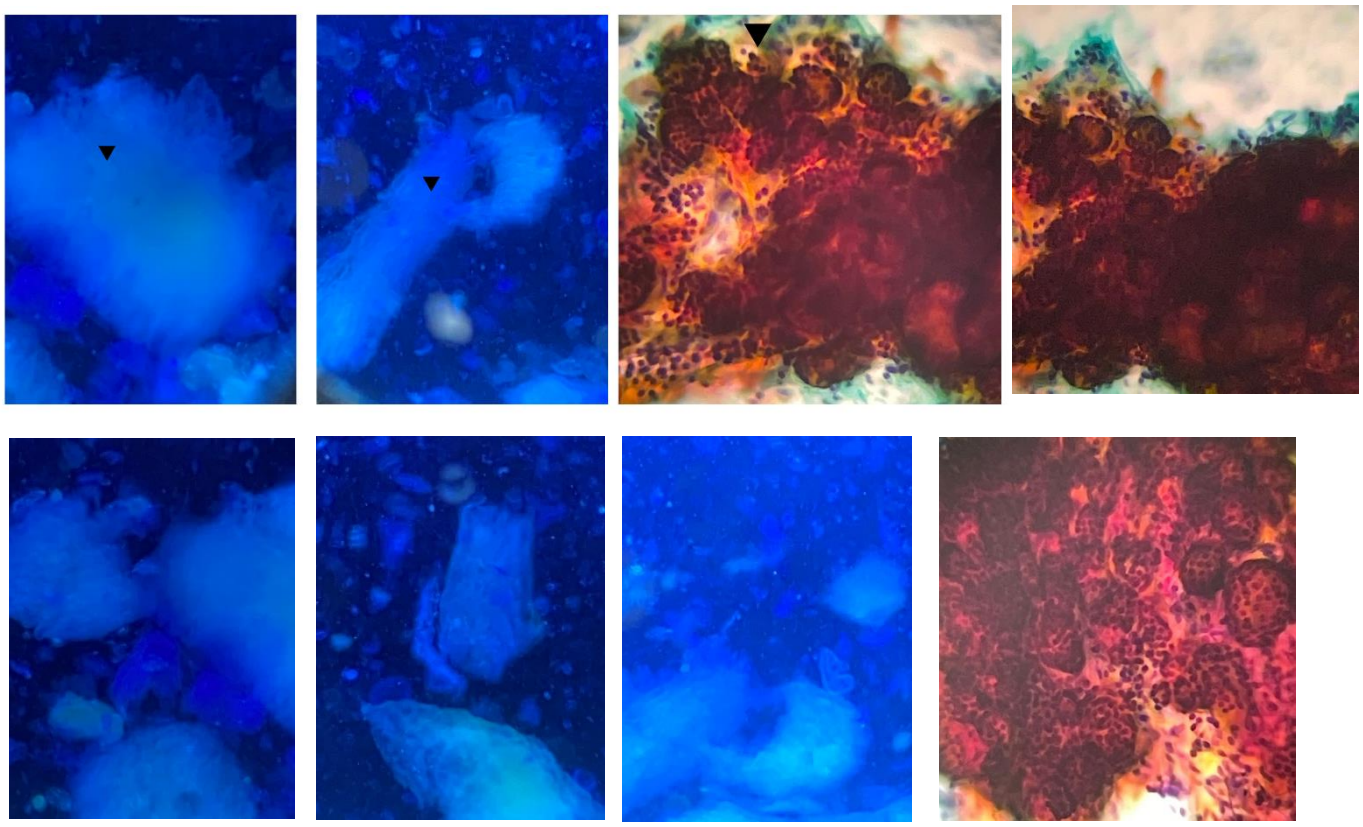

【悪性：甲状腺乳頭癌】　▼　（濃青色で立体的な不規則集塊像）

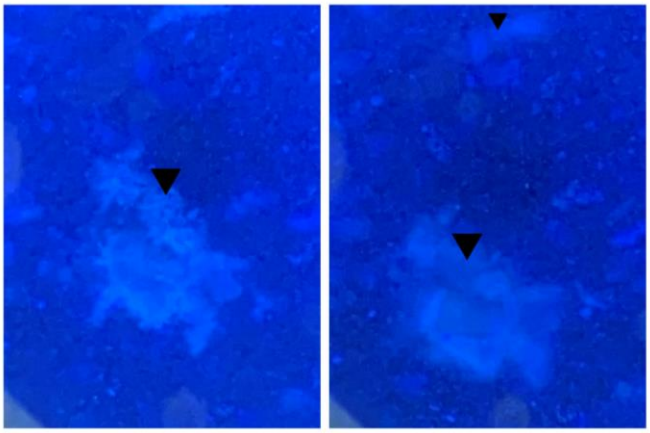

MR 観察像

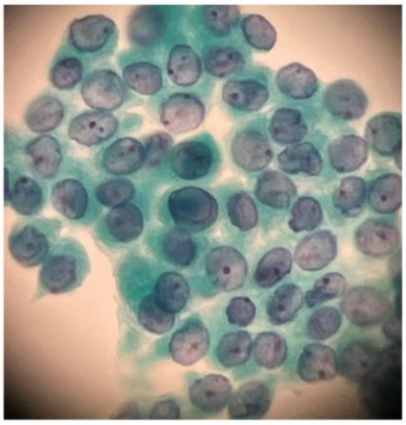

PAP 染色

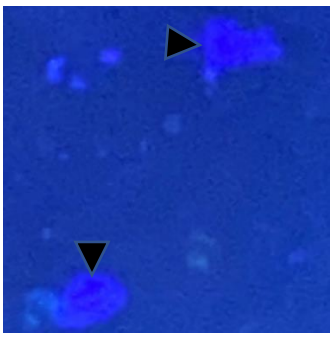

MR 観察像

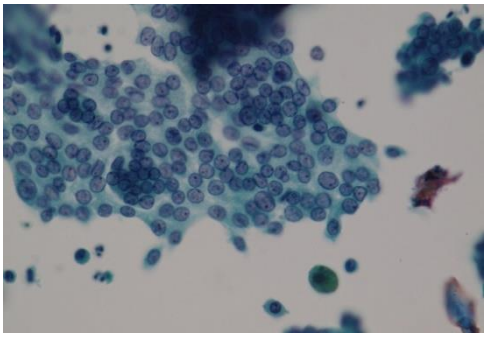

PAP 染色